

Mazur E. S.¹, Mazur V. V.¹, Rabinovich R. M.², Myasnikov K. S.², Bachurina M. A.²

¹ Tver State Medical University, Tver, Russia

² Tver Regional Clinical Hospital, Tver, Russia

ON THE CAUSES OF ANGINA PECTORIS IN PATIENTS WITH PULMONARY EMBOLISM

<i>Objective</i>	Compare the distance between the pulmonary artery (PA) and the left coronary artery (LCA) using pulmonary angiography and the rate of detection of the signs of left ventricular myocardial ischemia in the first electrocardiogram (ECG) in pulmonary embolism (PE) patients with or without angina to detect possible causes of angina pectoris.
<i>Material and Methods</i>	Measurement of the minimum distance between the PA and LCA in multislice spiral computed tomography and analysis of the first ECG were performed in 55 PE patients. 15 (27.3%) patients had angina pectoris at the onset of the disease.
<i>Results</i>	Angina pectoris was observed in 14 (93.3%) of 15 patients with the distance between the PA and LCA less than 4.3 mm, and in one (2.5%) of 40 patients with the distance between these vessels equal to or exceeding the specified value ($p < 0.001$). In the first ECG, the ST elevation in the aVR lead was detected in 10 (66.7%) patients with angina pectoris, and only in 3 (7.5%) patients without angina pectoris ($p < 0.001$).
<i>Conclusions</i>	The findings suggest that angina pectoris in acute pulmonary embolism may be caused by compression of the LCA by the dilated PA.
<i>Keywords</i>	Pulmonary embolism; angina pectoris; myocardial ischemia; left coronary compression
<i>For citation</i>	Mazur E. S., Mazur V. V., Rabinovich R. M., Myasnikov K. S., Bachurina M. A. On the Causes of Angina Pectoris in Patients with Pulmonary Embolism. <i>Kardiologiia</i> . 2020;60(1):28–34. [Russian: Мазур Е. С., Мазур В. В., Рабинович Р. М., Мясников К. С., Бачурина М. А. К вопросу о причинах появления ангинозных болей при тромбоэмболии легочной артерии. <i>Кардиология</i> . 2020;60(1):28–34]
<i>Corresponding author</i>	Mazur Evgeniy. E-mail: mazur-tver@mail.ru

Pulmonary embolism (PE) is often accompanied by substernal chest pain [1] – that is, angina – as, according to a majority of researchers, PE is caused by right ventricular (RV) ischemia, which develops when the pulmonary artery (PA) pressure surges [2, 3]. RV overload and limited blood supply associated with the increased pressure in the intramural vessels contribute to the development of ischemia [3]. PE causes a compensatory increase in RV systolic tension and, consequently, an increase in the pressure in the intramural vessels, which reduces systolic blood flow to the myocardium and, combined with the increased myocardial oxygen demand, causes the development of ischemia. If shock occurs, the systolic pressure gradient between the aorta and intramural vessels of the right ventricle can fall to near zero, contributing to an acute decrease in systolic coronary blood flow in the RV myocardium and the development of severe ischemic injury with a significant increase in blood troponin levels [4].

While the possibility of RV ischemia in PE is indisputable, it is recognized that some facts cannot be explained within this concept of the development of substernal chest pain. For instance, angina pectoris in PE is observed in about 15% of cases [1], while the hemodynamic abnormalities that can cause RV overload

and ischemia occur in 25% of patients [2, 5], and an increase in the troponin levels, showing the development of ischemic injury, is registered in 50% of patients [1, 6].

A discrepancy between the rate of angina pectoris and the detection rate of signs of RV ischemic injury in PE can have two explanations. First, we can assume that RV ischemia is often silent, and therefore the rate of angina pectoris in PE is lower than that of signs of RV ischemic injury. Second, it can be suggested that angina pectoris in PE is associated with left ventricular (LV) rather than RV ischemia.

Numerous clinical observations and the findings of several trials are found in the literature that show that angina attacks in patients with chronic pulmonary hypertension can be associated with compression of the main left coronary artery (LCA) by the dilated PA [7–11]. We could not find studies of compression of the LCA by the pulmonary artery as a cause of angina in acute PE, which prompted us to perform this study.

The objective of the study was to compare the distance between the PA and the LCA (PA-LCA distance) using pulmonary angiography and the rate of detection of signs of LV myocardial ischemia in the first ECG in PE patients with or without angina to detect possible causes of angina pectoris.

Material and Methods

We examined the medical records of 55 patients with PE who were hospitalized in Tver Regional Clinical Hospital in 2017–2018. Patients included in the study were selected according to the following criteria:

- 1) Description of the complaints made it possible to explicitly conclude whether or not angina pectoris was present at the onset of the disease.
- 2) The patient had no history of clinical manifestations of coronary heart disease (myocardial infarction or exertional angina) and/or coronary interventions.
- 3) Records included an ECG performed at the first medical contact with the patient.
- 4) Blood levels of high-sensitivity cardiac troponin I were measured at admission or after revealing PE using contrast-enhanced multislice spiral computed tomography (CT) of PA (CT pulmonary angiography).
- 5) RV dimensions, the amplitude of the tricuspid annular plane systolic excursion (TAPSE), and PA systolic pressure (PASP) were measured at echocardiography (EchoCG).
- 6) Records included a CT pulmonary angiogram in DICOM format, available for additional analysis. The mean age of patients included in the study (30 male and 25 female) was 58 years (interquartile range: 46–65 years). The majority of patients (n=50) had PE risk factors: hypertension (n=44), recent surgery or injury (n=20), age older than 64 years (n=15), history of venous thromboembolism (n=13), chronic pulmonary diseases with respiratory distress (n=8), type 2 diabetes mellitus (n=8), chronic heart failure (n=7), cancer (n=6).

Fifteen (27.3%) of 55 patients included in the study had angina pectoris at the onset of the disease.

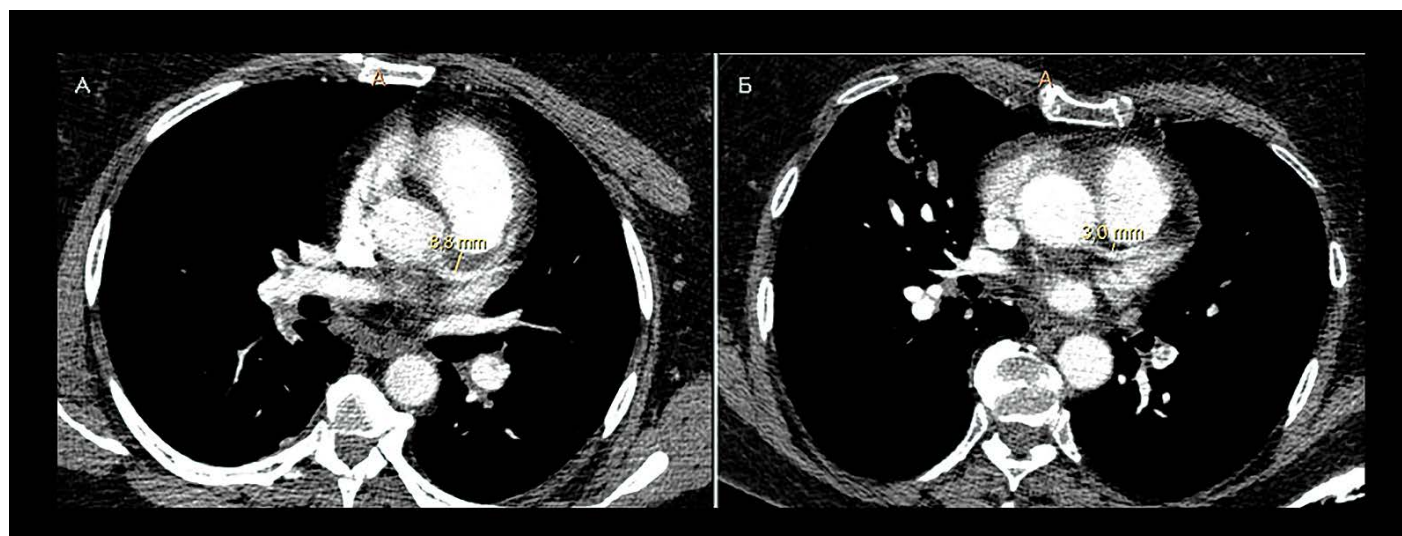
According to the criteria of the European Society of Cardiology [12], PE with a high risk of death was diagnosed in 14 (25.5%) patients, with medium risk of death in 30 (54.5%) patients and low risk of death in 11 (20.0%) patients.

T-wave inversion in leads V_1 – V_4 , ST-segment elevation ≥ 1 mm in leads aVR and V_1 , and ST-segment depression ≥ 1 mm in any lead were taken into account when analyzing the first ECG. T-wave inversion in the specified leads is included in the ECG score used to assess the probability of PE [13], but it can also be a sign of myocardial ischemia [14, 15]. ST-segment elevation in leads aVR and V_1 is often observed in impaired coronary blood flow in LCA [16–18], and horizontal ST-segment depression is considered to be a rather sensitive and specific sign of subendocardial ischemia [19, 20].

CT pulmonary angiography, which was used to diagnose PE, was performed using the Phillips Brilliance system with the administration of Scanlux (1 mL/kg) and ECG synchronization with diastole. Direct angiographic criteria of acute PE were a central filling defect of the entire lumen (occlusion) and a central partial filling defect surrounded by contrast material on a cross-sectional or longitudinal image; or a peripheral intraluminal filling defect forming an acute angle with the artery wall [21].

Additional analysis of the CT pulmonary angiogram included measuring the minimum distance between PA and LCA (Figure 1) and calculating the Qanadli obstruction index [22]. The obstruction index is expressed as a percentage of the maximum possible value

Figure 1. Measuring the distance between the pulmonary artery and the left coronary artery in computed pulmonary angiography in a patient with pulmonary embolism without (A) and with (B) angina pectoris



CT, computed tomography; PE, pulmonary embolism.

Table 1. Characteristics of PE patients with and without angina pectoris

Parameter	Angina pectoris		P
	yes (n=15)	no (n=40)	
Age, years	53.7 (45.0 – 62.4)	55.6 (50.5 – 60.7)	>0.05
Male	5 (33.3)	25 (62.5)	>0.05
PE risk factors	14 (93.3)	36 (90)	>0.05
Risk of early death			
• low	3 (20)	8 (20)	>0.05
• intermediate	7 (46.7)	23 (57.5)	
• high	5 (33.3)	9 (22.5)	
PA obstruction index, %	43.5 (30.1 – 56.9)	39.4 (32.9 – 45.9)	>0.05
PA diameter, cm	3.10 (2.80 – 3.40)	3.29 (3.05 – 3.53)	>0.05
PA-LCA distance, mm	2.85 (2.28 – 3.42)	7.78 (7.07 – 8.49)	<0.001
Troponin I, pg/L	98.3 (27.4 – 169.2)	81.6 (46.6 – 116.6)	>0.05
PASP, mm Hg	51.5 (40.9 – 62.1)	52.5 (46.5 – 58.5)	>0.05
RV dimension, cm	3.27 (3.00 – 3.54)	3.44 (3.22 – 3.66)	>0.05
TAPSE, cm	1.71 (1.50 – 1.92)	1.70 (1.53 – 1.87)	>0.05
T _{V1-V4} inversion	10 (66.7)	18 (45)	>0.05
ST _{aVR} elevation	10 (66.7)	3 (7.5)	<0.001
ST _{V1} elevation	5 (33.3)	1 (2.5)	<0.02
ST depression	7 (46.7)	4 (10)	<0.02

Data are presented as the arithmetic mean (M) and 95% confidence interval CI), or as the absolute and relative values – abs (%).
PE, pulmonary embolism; PA, pulmonary artery; LCA, left coronary artery; PASP, pulmonary artery systolic pressure;
RV, right ventricle; TAPSE, tricuspid annular plane systolic excursion.

Table 2. Characteristics of PE patients according to risk of early death

Parameter	Risk of early death		
	High (n=14)	Intermediate (n=30)	Low, (n=11)
Age, years	56.7 (46.5 – 66.9)	56.9 (51.7 – 62.1)	48.1 (36.7 – 59.5)
Male, n (%)	8 (57.1)	16 (53.3)	6 (54.5)
PE risk factors, n (%)	14 (100)	27 (90)	9 (81.8)
Angina pectoris, n (%)	4 (28.6)	6 (20.0)	3 (27.3)
PA obstruction index, %	52.7 (40.5 – 64.8)	43.8 (37.1 – 50.3)	16.4 (10.2 – 22.5) p ₁ <0.01; p ₂ <0.01
PA diameter, cm	3.36 (3.06 – 3.66)	3.41 (3.14 – 3.68)	2.62 (2.23 – 3.01) p ₁ <0.01; p ₂ <0.01
PA-LCA distance, mm	5.59 (3.80 – 7.38)	6.88 (5.83 – 7.93)	6.28 (or 4.13 Δo 8.43)
Troponin I, pg/L	181 (110 – 253)	71.9 (34.1 – 110) p ₁ <0,01	8.7 (or 0.60 Δo 16.8) p ₁ <0.01; p ₂ <0.01
PASP, mm Hg	57.7 (52.1 – 63.3)	56.9 (49.5 – 64.3)	32.5 (or 25.9 Δo 39.1) p ₁ <0.01; p ₂ <0.01
RV dimension, cm	3.79 (3.51 – 4.08)	3.48 (3.27 – 3.69)	2,66 (or 2.41 Δo 2.91) p ₁ <0.01; p ₂ <0.01
TAPSE, cm	1.38 (1.17 – 1.58)	1.72 (1,54 – 1.90) p ₁ <0,05	2,08 (or 1.84 Δo 2.31) p ₁ <0.01; p ₂ <0.05
T _{V1-V4} inversion	12 (85.7)	14 (46.7) p ₁ <0.05	2 (18.2) p ₁ <0.005
ST _{aVR} elevation	4 (28.6)	7 (23.3)	2 (18.2)
ST _{V1} elevation	3 (21.4)	2 (6.7)	1 (9.1)
ST depression	4 (28.6)	6 (20)	1 (9.1)

Data are presented as the arithmetic mean and 95% confidence interval – M (95% CI), or as the absolute and relative values – abs (%);
p₁ – a difference with the group of patients at high risk of early death; p₂ – a difference with the group of patients at intermediate risk.
PE, pulmonary embolism; PA, pulmonary artery; LCA, left coronary artery; PASP, pulmonary artery systolic pressure;
RV, right ventricle; TAPSE, tricuspid annular plane systolic excursion.

(i.e., 40 points), which corresponds to complete occlusion of the main PA or both branches [22].

EchoCG was carried out in PE patients under medium or low risk of early death on the same day as CT pulmonary angiography, which allowed us to compare the data obtained in these examinations. PE patients at high risk of early death underwent EchoCG after they had been brought out of shock, (i.e., after thrombolytic therapy). Thus, the data obtained using EchoCG during CT pulmonary angiography could be compared with the PA obstruction indices and PA diameters.

Statistical analysis of data was performed using SPSS Statistics version 15.0. Statistical analysis of the collected data involved the comparison of patients with and without angina pectoris, and the comparison of PE patients at high, medium, and low risk of early death. In patients at high risk, the statistical significance of the intergroup differences of the quantitative means was assessed with the Student's t-test (normal distribution) and the Mann-Whitney U-test (displaced distribution). In patients at low risk of early death, one-way analysis of variance (ANOVA) with assessment of intergroup differences was performed by Newman-Keuls test (normal distribution), and the nonparametric Kruskal-Wallis test with the assessment of the intergroup differences by Dunn's test (displaced distribution). The data are presented as the arithmetic mean (M) and 95% confidence interval (CI). Frequency analysis was performed using the χ^2 test or the Fisher's exact test and Bonferroni correction in the case of multiple intergroup comparisons. Receiver operating characteristic curve (ROC) analysis was also performed, allowing us to determine the value of a quantitative characteristic, dividing study subjects into two qualitatively different groups.

The objective of this analysis was to determine the PA-LCA distance, which makes it possible to differentiate PE patients with and without angina pectoris.

Results

Groups of patients with and without angina pectoris were comparable in age, sex, and prevalence of PE risk factors (Table 1). There were no intergroup differences or differences in the distribution of patients in terms of the risk of early death, PA obstruction index and PA diameter, troponin levels, pressure in PA, and condition of the right ventricle.

The difference in the mean distance between PA and LCA (PA-LCA distance) was significant and strongly pronounced.

The mean value of PA-LCA distance in patients with angina pectoris was 2.5 times higher than in the control patients. ROC-analysis showed that the PA-LCA distance

equal to 4.3 mm is a cutoff point between PE patients with and without angina pectoris (sensitivity, 98%; specificity, 93%; area under the ROC curve, 97.4%).

The T-wave inversion in leads V_1 – V_4 was observed in PE patients with and without angina pectoris at an equal rate. However, both ST-segment depression and elevation in leads aVR and V_1 occurred in PE patients with angina pectoris at a much higher rate than in the control group.

The groups of PE patients at high, medium, and low risk of early death were comparable in terms of age, sex, prevalence of PE risk factors, proportion with angina pectoris at the onset of PE, mean PA-LCA distance, and rate of ST-segment deviations (Table 2).

The difference between PE patients at low risk of early death and the high- and medium-risk patients was significant in terms of other relevant characteristics: PE patients at low risk of early death had significantly lower mean values of PA obstruction index, PA diameter, blood troponin levels, PA pressure, and RV dimension. In addition, mean TAPSE indicative of the global systolic RV function in PE patients at low risk of early death exceeded that of the high- and medium-risk patients. T-wave inversion in the chest leads occurred in PE patients at low risk of early death at rates significantly lower than in the high- and medium-risk patients.

PE patients at high and medium risk of early death did not differ in terms of PA obstruction index, PA diameter, PA-LCA distance, PA pressure, RV dimensions, or the rate of the ST-segment depression and elevation. However, blood troponin levels in PE patients at high risk of early death were 2.5 times higher than in the medium-risk patients, while the mean TAPSE value in the high-risk patients was 0.35 (0.34–0.36) cm less than in the medium-risk patients. The rate of T-wave inversion in leads V_1 – V_4 in PE patients at high risk of early was almost two times higher than in the medium-risk patients.

Thus, PE patients with or without angina pectoris included in this study differed only in the mean PA-LCA distance and rate of ST-segment deviations in ECG. PE patients at high and medium risk of early death differed in terms of troponin levels, LV systolic function, and the rate of T-wave inversion in leads V_1 – V_4 .

Discussion

Discussion of study results may appropriately start with analysis of the comparative data of PE patients of high, medium, and low risk of early death. The pronounced difference in these characteristics on the part of patients with a low risk of pulmonary embolism compared to those patients designated as of high and medium risk is explained by the inclusion in the latter groups of patients without pancreatic overload or an

increase in the level of troponins in the blood. The apparent reason for these differences is a significantly less severe thromboembolic obstruction of the pulmonary arterial bed, and correspondingly near-normal PA pressure. Thus, PE patients at low risk of early death had neither hemodynamic prerequisites for the development of RV ischemia nor objective evidence of ischemic injury. However, one in four of these patients had angina pectoris at the onset of the disease, which given the above, cannot be explained by RV ischemia.

PE patients at high or medium risk of early death were comparable in mean obstruction index and PA diameter – that is, hemodynamic overload of RV at the onset of the disease is almost equal. However, troponin levels in PE patients at high risk of early death was 2.5 times higher on average than in the medium-risk patients. More severe RV injury in PE patients, causing the development of obstructive shock, can be associated with impaired RV blood supply during systole due to the pressure drop in the aorta.

When PE patients at high risk of early death were brought out of shock, the PA pressure level was comparable to the pressure levels in the medium-risk patients. There were no statistically significant differences in RV dimensions. However, mean TAPSE indicative of the global systolic RV function in PE patients at high risk of early death was significantly lower than that in the medium-risk patients. More severe RV systolic dysfunction in PE patients at high risk of early death can be associated with more severe myocardial ischemic injury in the acute phase of the disease.

The rate of T-wave inversion in the chest leads was significantly higher in PE patients at high risk of early death than in medium-risk patients. Taking the foregoing into account, it can be suggested that T-wave inversion in the right chest leads is associated with RV ischemia. Several researchers [14, 23–25] share this opinion; however, generally, the causes of this phenomenon remain a subject of dispute [15].

Thus, PE patients at medium and, especially, high risk of early death had hemodynamic prerequisites for the development of RV ischemia and objective evidence of RV ischemic injury. However, the rate of angina pectoris in these patients was not higher than in PE patients at low risk of early death. This means that no evidence showing that angina pectoris in PE patients is associated with RV ischemia was obtained in this study.

PE patients with and without angina pectoris at the onset of the disease were comparable in terms of most relevant symptoms, but PA-LCA distance in patients with angina pectoris was 2.5 times less on average than in patients without angina pectoris. ROC analysis showed

that a cutoff point between these patients is PA-LCA distance = 4.3 mm. Angina pectoris was observed in 14 (93.3%) of 15 patients who had a PA-LCA distance of less than 4.3 mm, and in one (2.5%) of 40 patients with this distance equal to or exceeding the specified value. This patient had a PA-LCA distance equal to 5.4 mm (i.e., not significantly exceeding the cutoff point).

Results presented suggest that anatomic proximity of PA to LCA may be a prerequisite for the occurrence of angina pectoris in pulmonary embolism due to compression of LCA by dilated PA. This suggestion is supported by the fact that PE patients with angina pectoris at the onset of the disease often had ECG signs of LV ischemia, including those characteristic of impaired blood flow in LCA.

It should be recalled that in the first ECG, ST-segment depression, including in the left chest leads, was observed in 50% of patients with angina pectoris at the onset of the disease and in only 1 of 10 control patients. However, according to the majority of researchers [15, 19, 26], ST-segment depression in the left chest leads in PE patients is associated with the development of LV ischemia.

The rate of ST-segment elevation in V_1 in patients with angina pectoris was 13 times higher and 9 times higher in aVR than in control patients. These ECG changes may occur in both RV ischemia and anterior LV wall ischemia associated with injuries of the orifice of the left anterior descending artery or the left main coronary artery. However, in RV ischemia, ST-segment elevation in V_1 and/or aVR is combined with ST-segment elevation in lead III, which reflects the distribution of ischemia to both the anterior and inferior RV walls [20, 26, 27]. In our study, no cases of the combination of ST-segment elevation in leads V_1 or aVR with ST-segment elevation in lead III were reported, which allows considering the ECG changes to be a manifestation of LV ischemia.

The absence of difference in the troponin levels in PE patients with and without angina pectoris is an indirect confirmation of the left ventricular origin of angina pectoris, as severe impairment of blood flow in LCA, which may cause a severe increase in the troponin levels, is usually not compatible with life.

Because coronary angiography is not a standard examination in PE patients we were not able to obtain direct evidence of LCA compression by PA in this study. Moreover, the lack of such results in the study allows suggesting that LV ischemia is a consequence of coronary atherosclerosis, which, being asymptomatic in normal life conditions, is hemodynamically significant in PE. Since half of the individual subjects were older than 58 years, it is reasonable to assume the presence of coronary atherosclerosis.

However, if the LV ischemia is caused by coronary atherosclerosis, angina pectoris and ECG signs of myocardial ischemia are manifest mostly in cases where the increase in myocardial oxygen demand due to higher heart rate is combined with the reduction in perfusion pressure in the coronary arteries – that is, in PE patients at high risk of early death. In PE patients at low risk of early death, who have no significant hemodynamic disorders, the rate of myocardial ischemia should, on the contrary, be very low. However, in this study, the rate of angina pectoris and ECG signs of myocardial ischemia in PE patients at high, medium, and low risk of early death was nearly equal, contradicting the hypothesis that the leading cause of LV ischemia in PE is coronary atherosclerosis.

Thus, the general finding of this study is consistent with the conclusion made by Galie et al. [11]: LCA compression by dilated PA may cause LV ischemia and the occurrence of angina pectoris. In patients with chronic pulmonary hypertension, LCA compression occurs in chronic dilation of PA of more than 40 mm [9, 11]. In this case, as in atherosclerotic stenosis of

LCA, ischemia occurs with increasing LV load and is manifested by exertional angina attacks. The anatomic proximity of PA and LCA (i.e., the distance between these arteries not exceeding 4.3 mm) is a prerequisite for the development of compression in PE. In this case, acute dilation of PA can cause LCA compression, LV ischemia, and angina pectoris. Reducing pressure in PA leads to a decrease in dilation, the disappearance of compression, and relief of pain.

Conclusions

The findings of this study suggest that angina pectoris in pulmonary embolism can be caused by compression of the left main coronary artery by a dilated pulmonary artery, and that the anatomic proximity of the left coronary artery to the pulmonary artery is a prerequisite for the development of its compression.

No conflict of interest is reported.

The article was received on 10/08/19

REFERENCES

- Pollack CV, Schreiber D, Goldhaber SZ, Slattery D, Fanikos J, O'Neil BJ et al. Clinical Characteristics, Management, and Outcomes of Patients Diagnosed With Acute Pulmonary Embolism in the Emergency Department. *Journal of the American College of Cardiology*. 2011;57(6):700–6. DOI: 10.1016/j.jacc.2010.05.071
- Kreit JW. The Impact of Right Ventricular Dysfunction on the Prognosis and Therapy of Normotensive Patients With Pulmonary Embolism. *Chest*. 2004;125(4):1539–45. DOI: 10.1378/chest.125.4.1539
- Gómez A, Bialostozky D, Zajarias A, Santos E, Palomar A, Martínez ML et al. Right ventricular ischemia in patients with primary pulmonary hypertension. *Journal of the American College of Cardiology*. 2001;38(4):1137–42. DOI: 10.1016/S0735-1097(01)01496-6
- Sandrikov V.A., Sadovnicov V.I., Polozhiev A.V. Complex analysis of the results of the functional research methods – necessary reality. *Ultrasound and Functional Diagnostics*. 2005;6:100–10. [Russian: Сандриков В.А., Садовников В.И., Положиев А.В. Комплексный анализ результатов функциональных методов исследования – необходимая реальность. *Ультразвуковая и функциональная диагностика*. 2005;6:100–10]
- Bova C, Greco F, Misuraca G, Serafini O, Crocco F, Greco A et al. Diagnostic utility of echocardiography in patients with suspected pulmonary embolism. *The American Journal of Emergency Medicine*. 2003;21(3):180–3. DOI: 10.1016/S0735-6757(02)42257-7
- Becattini C, Vedovati MC, Agnelli G. Prognostic Value of Troponins in Acute Pulmonary Embolism: A Meta-Analysis. *Circulation*. 2007;116(4):427–33. DOI: 10.1161/CIRCULATIONAHA.106.680421
- Simakova M.A., Marukyan N.V., Gukov K.D., Zverev D.A., Moiseva O.M. Left main coronary artery compression by pulmonary artery aneurism in patients with long standing pulmonary arterial hypertension. *Kardiologiya*. 2018;58(11S):22–32. [Russian: Симакова М.А., Марукян Н.В., Гуков К.Д., Зверев Д.А., Моисеева О.М. Компрессия ствола левой коронарной артерии аневризмой ствола легочной артерии у пациентов с длительно существующей легочной артериальной гипертензией. *Кардиология*. 2018;58(11S):22–32]. DOI: 10.18087/cardio.2580
- Albadri K, Jensen JM, Christiansen EH, Mellemkjær S, Nielsen-Kudsk JE. Left Main Coronary Artery Compression in Pulmonary Arterial Hypertension. *Pulmonary Circulation*. 2015;5(4):734–6. DOI: 10.1086/683690
- Dodd JD, Maree A, Palacios I, de Moor MM, Mooyaart EAQ, Shapiro MD et al. Left Main Coronary Artery Compression Syndrome: Evaluation With 64-Slice Cardiac Multidetector Computed Tomography. *Circulation*. 2007;115(1):e7–8. DOI: 10.1161/CIRCULATIONAHA.106.645622
- Sugiyama K, Koizumi N, Ogino H. Severe Compression of the Left Main Coronary Artery in a Patient with Chronic Thromboembolic Pulmonary Hypertension. *Annals of Thoracic and Cardiovascular Surgery*. 2018;24(5):251–4. DOI: 10.5761/atcs.cr.17-00084
- Galiè N, Saia F, Palazzini M, Manes A, Russo V, Bacchi Reggiani ML et al. Left Main Coronary Artery Compression in Patients With Pulmonary Arterial Hypertension and Angina. *Journal of the American College of Cardiology*. 2017;69(23):2808–17. DOI: 10.1016/j.jacc.2017.03.597
- Authors/Task Force Members, Konstantinides SV, Torbicki A, Agnelli G, Danchin N, Fitzmaurice D et al. 2014 ESC Guidelines on the diagnosis and management of acute pulmonary embolism. *European Heart Journal*. 2014;35(43):3033–80. DOI: 10.1093/eurheartj/ehu283
- Daniel KR, Courtney DM, Kline JA. Assessment of Cardiac Stress From Massive Pulmonary Embolism With 12-Lead ECG. *Chest*. 2001;120(2):474–81. DOI: 10.1378/chest.120.2.474
- Choi B-Y, Park D-G. Normalization of Negative T-Wave on Electrocardiography and Right Ventricular Dysfunction in Patients with an Acute Pulmonary Embolism. *The Korean Journal of Internal Medicine*. 2012;27(1):53–9. DOI: 10.3904/kjim.2012.27.1.53
- Digby GC, Kukla P, Zhan Z-Q, Pastore CA, Piotrowicz R, Schapachnik E et al. The Value of Electrocardiographic Abnormalities in the Prognosis of Pulmonary Embolism: A Consensus Paper: Pulmonary Embolism & ECG. *Annals of Noninvasive Electrocardiology*. 2015;20(3):207–23. DOI: 10.1111/anec.12278

16. Yan AT, Yan RT, Kennelly BM, Anderson FA, Budaj A, López-Sendón J et al. Relationship of ST elevation in lead aVR with angiographic findings and outcome in non-ST elevation acute coronary syndromes. *American Heart Journal*. 2007;154(1):71–8. DOI: 10.1016/j.ahj.2007.03.037
17. Ibanez B, James S, Agewall S, Antunes MJ, Bucciarelli-Ducci C, Bueno H et al. 2017 ESC Guidelines for the management of acute myocardial infarction in patients presenting with ST-segment elevation: The Task Force for the management of acute myocardial infarction in patients presenting with ST-segment elevation of the European Society of Cardiology (ESC). *European Heart Journal*. 2018;39(2):119–77. DOI: 10.1093/eurheartj/ehx393
18. Williamson K, Mattu A, Plautz CU, Binder A, Brady WJ. Electrocardiographic applications of lead aVR. *The American Journal of Emergency Medicine*. 2006;24(7):864–74. DOI: 10.1016/j.ajem.2006.05.013
19. Zhong-qun Z, Chong-quan W, Nikus KC, Sclarovsky S, Chao-rong H. A new electrocardiogram finding for massive pulmonary embolism: ST elevation in lead aVR with ST depression in leads I and V4 to V6. *The American Journal of Emergency Medicine*. 2013;31(2):456.e5–456.e8. DOI: 10.1016/j.ajem.2012.08.001
20. Hennings JR, Fesmire FM. A new electrocardiographic criteria for emergent reperfusion therapy. *The American Journal of Emergency Medicine*. 2012;30(6):994–1000. DOI: 10.1016/j.ajem.2011.04.025
21. Stein PD, Fowler SE, Goodman LR, Gottschalk A, Hales CA, Hull RD et al. Multidetector Computed Tomography for Acute Pulmonary Embolism. *New England Journal of Medicine*. 2006;354(22):2317–27. DOI: 10.1056/NEJMoa052367
22. Qanadli SD, El Hajjam M, Vieillard-Baron A, Joseph T, Mesur-olle B, Oliva VL et al. New CT Index to Quantify Arterial Obstruction in Pulmonary Embolism: Comparison with Angiographic Index and Echocardiography. *American Journal of Roentgenology*. 2001;176(6):1415–20. DOI: 10.2214/ajr.176.6.1761415
23. de Luna AB, Zareba W, Fiol M, Nikus K, Birnbaum Y, Baranowski R et al. Negative T Wave in Ischemic Heart Disease: A Consensus Article: Negative T Wave in Ischemic Heart Disease. *Annals of Non-invasive Electrocardiology*. 2014;19(5):426–41. DOI: 10.1111/anec.12193
24. Kukla P, McIntyre WF, Fijorek K, Długopolski R, Mirek-Bryniarska E, Bryniarski KL et al. T-wave inversion in patients with acute pulmonary embolism: Prognostic value. *Heart & Lung*. 2015;44(1):68–71. DOI: 10.1016/j.hrtlng.2014.10.003
25. Kosuge M, Kimura K, Ishikawa T, Ebina T, Hibi K, Kusama I et al. Electrocardiographic Differentiation Between Acute Pulmonary Embolism and Acute Coronary Syndromes on the Basis of Negative T Waves. *The American Journal of Cardiology*. 2007;99(6):817–21. DOI: 10.1016/j.amjcard.2006.10.043
26. Kukla P, Kosior DA, Tomaszewski A, Ptaszyńska-Kopczyńska K, Widejko K, Długopolski R et al. Correlations between electrocardiogram and biomarkers in acute pulmonary embolism: Analysis of ZATPOL-2 Registry. *Annals of Noninvasive Electrocardiology*. 2017;22(4):e12439. DOI: 10.1111/anec.12439
27. Kukla P, McIntyre WF, Fijorek K, Mirek-Bryniarska E, Bryniarski L, Krupa E et al. Electrocardiographic abnormalities in patients with acute pulmonary embolism complicated by cardiogenic shock. *The American Journal of Emergency Medicine*. 2014;32(6):S07–10. DOI: 10.1016/j.ajem.2014.01.043